Analysis of frequency and effectiveness of gonad shield use during diagnostic hip radiology

Ewa Pasieka[1], Magdalena Żelechowicz[1], Robert Milewski[2]

[1] Department of Radiology, Medical University of Bialystok, Poland

[2] Department of Statistics and Medical Informatics, Medical University of Bialystok, Poland

European Journal of Medical Technologies
2017; 1(14): 1-7

www. medical-technologies.eu
Published online 20.04.2017

Abstract

Purpose: Use of shields on radiosensitive organs during diagnostic radiology is a condition for reducing the radiation dose to the patient. While taking pelvic region radiographs, gonad shields should be used, so long as this action does not reduce the radiograph's diagnostic value. The aim of this study was retrospective analysis of use of gonad shields during diagnostic radiology of the hip joints.

Materials and methods: We conducted a retrospective analysis of subsequent 216 comparative X-ray images of hips taken of male patients at the Department of Radiology, Medical University Hospital in Bialystok, from February 1 to October 31, 2014. The radiographs were evaluated for use of gonad shields and effectiveness. For the purposes of the study, we created an effectiveness scale with the following grades: 0 – no shield, 0.1 – shield does not cover gonads, 1.0 – shield partially covers gonads, 1 – shield covers gonads completely.

Results: Gonad shields were used on 31 (14%) patients aged from 22 to 81 years (M=49 years). The most numerous group on which gonad shields were used consisted of men under 40 years old (n=12; 39%); and in the case of 3 (10%) men, a grade 1 effectiveness was obtained. For 16 (52%) patients, the

Adres do korespondencji:
Ewa Pasieka
Department of Radiology, Medical University of Bialystok
ul. M. Skłodowskiej-Curie 24A
15-276 Białystok
+48 85 831 88 72
ewapass@poczta.onet.pl

Key words:

gonads, radiation protection, quality control, radiography

shield partially covered the gonads. On one X-ray, the shield was visible outside the patient's gonads.

Conclusions: Gonad shields were used on adult male patients during diagnostic radiology of the hip joints in only a few cases. This requires planning and implementation of effective corrective activities as a guarantee of reducing patient exposure.

Introduction

Radiation protection is defined as any measure taken by medical personnel to minimize the radiation dose received by the patient during ionizing radiation diagnostics and therapy. Protection of radiosensitive organs, such as male gonads, is a basic procedure [1]. The first reports on the need to use gonad shields in diagnostic radiology emerged in the late 1950s [2].

Contact shields, which are placed directly on the patient's body, are the most common type of male gonad protection. A shadow shield, which is attached to the collimator, is a less common solution. Contact shields absorb 95-99% of radiation within anode voltage range 50-100 kV. It is necessary to strictly follow the principles of protective shield use whenever possible, without reducing the diagnostic value of X-ray images and whenever the edge of the radiation field is within 5 cm of the gonads. Use of collimation so that the gonads are outside the direct beam, which, when combined with shielding reduces the organ dose to zero, is also significant [3-5]. In the case of diagnostic hip radiology in the anterior-posterior view (AP), male gonads are in the direct beam of X-ray radiation. Therefore, it is necessary to use properly located shields. Proper location can be considered in two aspects, i.e. shielding the gonads, but without covering bone structures such as the ischiadic and pubic bones [6].

Properly used radiation protection allows minimizing the effects of radiation. Over the last years, the gonad weighting factor of 0.2 topped the list of radiosensitive tissues and organs. In 2007, the International Commission on Radiological Protection (ICRP) made a correction and the current value of the factor is 0.08, which is the basis for effective dose calculation (Table 1) [7].

The male gonadal dose during radiography of both hips is 2.3 mGy, which is the highest permitted male gonadal exposure in standard diagnostic radiology. The diagnostic doses for other body regions are significantly lower, e.g. 0.014 mGy for lumbar spine AP, or the risk of exposure is zero, e.g. chest PA [8]. During an X-ray examination, the radiographer should consider factors affecting the size of the dose absorbed by the gonads [5,9]:

1. Exposure parameters
2. Sensitivity of the image detector
3. Primary beam collimation
4. Primary beam filtration
5. Patient positioning
6. Proper shield placement on patient's body
7. Thickness of shielding material

In Poland, the thickness of the gonad shield (regardless of gender) is 1 mm Pb, which is in accordance with current radiation protection regulations [10]. The following should be applied during hip X-ray imaging: anode voltage of 70-85 kV, sensitivity 400, filtration ≥ 3mmAl, collimation limited to the examined anatomical site (≤1200 cm^2), and an anti-scatter grid with a focal length matched with the focus-detector distance [11].

The aim of this study was to assess the frequency and effectiveness of gonad shield use during diagnostic hip radiology in adult male patients.

Materials and methods

The study was conducted using the diagnostic survey method. A retrospective analysis of hip X-rays was used. Subsequent 216 hip X-ray images were analyzed. All radiographs were taken at the Department of Radiology, Medical University Hospital in Bialystok, from February 1 to October 31, 2014 using Axiom Aristos Fx Plus Siemens.

Radiographs were evaluated for frequency of gonad shield use and effectiveness. Effectiveness was

Fig. 1.
Failure to use gonad shield

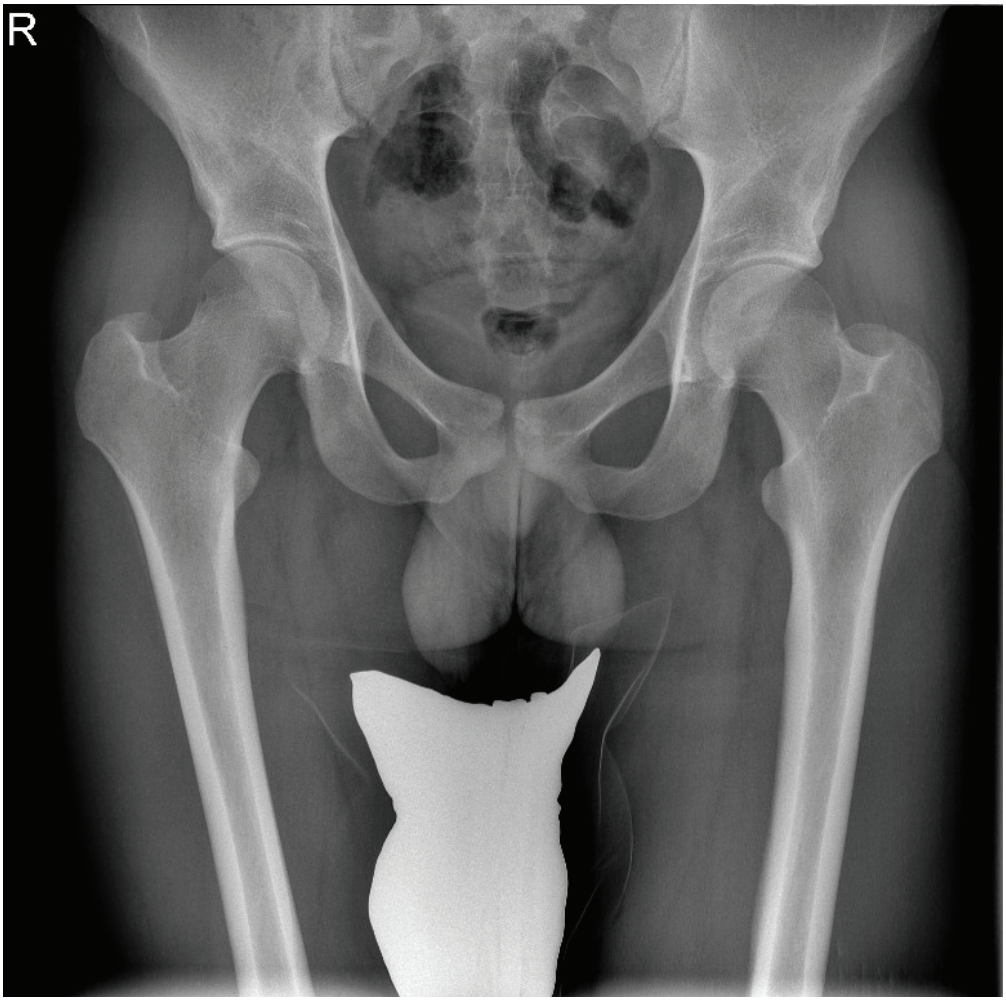

Fig. 2.
Shield does not cover gonads

Fig. 4.
Shield partially covers gonads

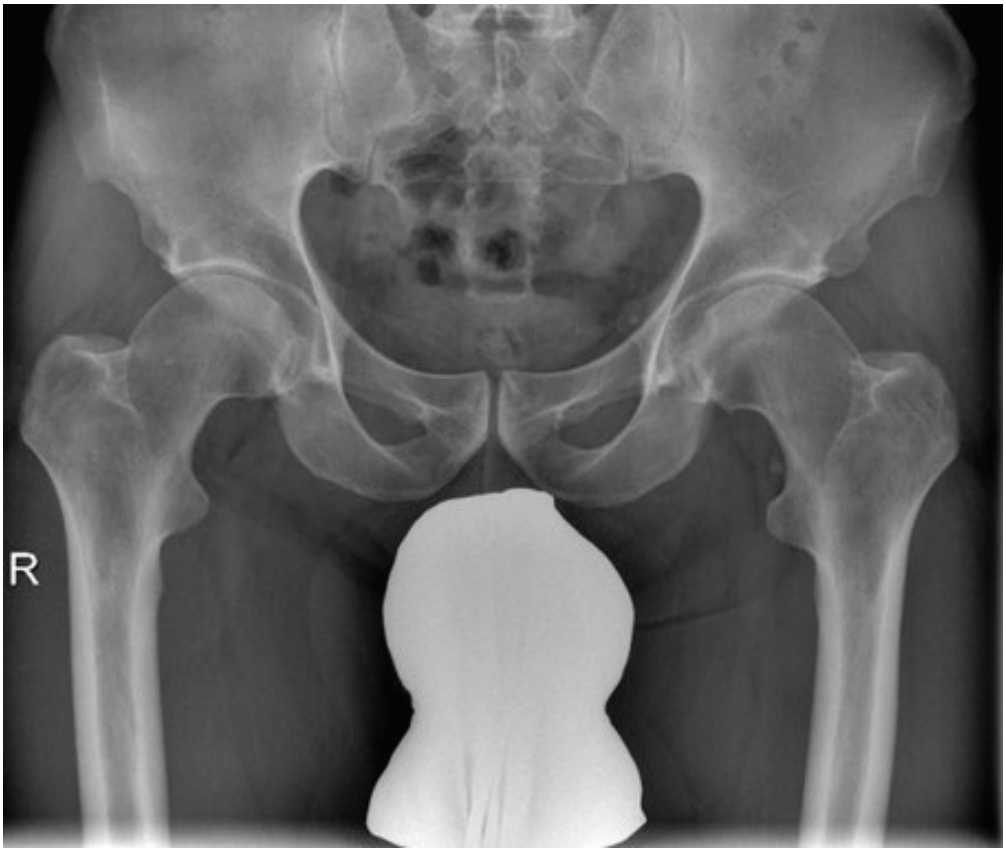

Fig. 3.
Shield covers gonads completely

analyzed using the authors' own scale (Table 2). All data obtained during the study was compiled using Microsoft Excel 2007. Statistical analysis was completed by applying the Chi-squared test (significance level $p<0,05$). Calculations were completed using Statistica 12.0 StatSoft.

Results

We analyzed 216 X-rays taken of male patients aged 22-87 years (Me=63). Gonad shields were used on 31 (14%) patients aged 22-81 years (Me=49). The most numerous group on which shields were used was ≤ 40 years old (n=12; 39%), then ≥ 60 years (n=10; 32%), and 41-59 years (n=9; 29%).

During X-ray imaging, a shield that correctly protected the gonads (criterion 1) was used on 14 men. We found criterion 0.1 – no protection despite shield use – on one radiograph. We observed criterion 1.0 – partial protection – on 16 X-rays.

In the group of patients ≤ 40 years old, the greatest percentage (n=7; 58%) constituted images that fulfilled criterion 1.0, and then those fulfilling criterion 1 (n=5; 42%). In the case of men aged 41-59 years, 56% X-rays (n=5) fulfilled criterion 1, and 44% (n=4) criterion 1.0. In the group with the oldest patients, the most often fulfilled criterion was 1.0 (n=5; 50%), then criterion 1 (n=4; 40%) and 0.1 (n=1; 10%).

In the case of 80% of X-rays, female shields were used to protect male gonads. The use of male shields was the most effective. Most of the radiographs where the exam was used this type of protection to meet criterion 1 ($\chi 2=9,034$, $p=0,002$).

Discussion

The use of gonad shields during hip radiography is an important aspect of patient radiation safety. The issue is not a common subject of analyses aiming to identify the problem and propose adequate corrective measures [1,12,13]. We found no studies assessing gonad shield use in Polish hospitals.

The outcomes of the analysis clearly indicate that male gonad shield use has been abandoned. Other authors drew similar conclusions. Doolan et al. showed that only 2% of pelvic X-ray procedures performed in Dublin hospitals used gonad shields [1]. In Norwegian hospitals, gonad shields were used in 18% of cases and 13% in the study by Behroozi et al. [12,13]. Slightly better results were reported for pediatric diagnostic radiology. Warlow et al. showed that effective gonadal shielding

Table 1.
Effective dose in diagnostic radiology of hip joints taking into account ICRP weighting factor recommendations [8].

Radiography of the hip joints (antero-posterior view)	Effective dose [mSv]	
	ICRP-60 (1991)	ICRP-103 (2007)
Single hip	0.15	0.087
Both hips	0.35	0.19

Table 2.
Effectiveness scale of gonad shield use.

Scope	Criterion	Example
0	Failure to use gonad shield	Fig. 1.
0.1	Shield does not cover gonads	Fig. 2.
1	Shield covers gonads completely	Fig. 3.
1.0	Shield partially covers gonads	Fig. 4.

(covering the entire scrotum) in boys was used in 29% of pelvic radiological procedures [14]. Slightly poorer rates (22%) were obtained by Musad et al., whereas higher rates (34%) were reported by Frantzen et al. [15,16].

In our study, gonad shields were most frequently used on patients under 40 years old. Thomas indicated the necessity of using male gonad shields in patients of all ages [17]. This is due to the difficulty of determining the upper limit of male reproductive age. Cessation of gonadal function is associated with the process of andropause and can affect 20-30% of men over 60 years old, 30-40% of men over 70, and 40-50% of men over 80 [18].

We found a high percentage of X-ray images taken without the use of shields or with improper shield location. This may be due to different reasons, such as haste or avoiding contact with the patient. Gonad shield use involves entering the patient's intimate zone, which may potentially result in abandoning their use by medical personnel [19]. However, cooperation with the patient based on dialog, respect for one's dignity, and understanding allow achieving the desired goals. Additionally, the introduction of the 'gonadal shielding' criterion into the analysis of rejected pelvic images would raise radiographers' awareness of the necessity of gonad shield use, and, consequently, optimize the procedure. Proposed by our classification can greatly facilitate this analysis.

Most of the analyzed X-ray images were taken with female gonad shields, which were appropriately adjusted (shaped), depending on the diagnostic requirements for a given patient. Although the thickness of the absorbing material is the same for male and female patients, its shape varies to match the anatomy. Our own studies have shown that dedicated particular sex shields are the most effective. A retrospective evaluation of radiographs does not allow answering the question why radiographers did not use gonad shields. It is likely that the facility where hip imaging took place was not permanently equipped with male gonad shields. Doolan et al. noted that X-ray rooms often lack basic means of patient radiological protection [1]. Rostamzadeh et al. showed that the problem of lack of gonadal shielding pertains to 1/3 of X-ray rooms, where the equipment was analyzed in terms of meeting the patient radiation safety criteria [20]. Keeping records of the means for radiation protection in a given X-ray room and a periodic review of needs by a radiation protection officer seems to be a simple solution.

Effective use of male gonadal shielding does not only relate to its proper placement on a patient's body, but also to periodical inspections for possible cracks. This is particularly important if the above described bending and shaping of the shield edges occurs. A permanently damaged shield, even if properly placed on the patient's body, will not fulfill its role. The usefulness of gonad shields should be assessed in each case of suspected damage or every 12 months at maximum [21]. The performed inspections should be recorded to confirm the shield's protective function. The inspection procedure for individual ionizing radiation shields should be included in the documentation of the Quality Assurance (QA) program. In Poland, regulations indicating the need to implement and maintain QA in diagnostic radiology were issued in 2000 [22].

In the last years we have seen a transition to digital imaging. The use of new technologies in imaging should go hand in hand with the principles of radiation protection.

Conclusions

1. Gonad shields were not used on every patient during diagnostic hip radiology. They were most frequently used on men aged less than 40 years. Most frequently, the shield was placed in such a way that it did not cover the patient's gonads.
2. Very often, radiographers used women's shields to protect male gonads.
3. Procedural changes during hip X-ray imaging are necessary to reduce men's radiation risk.
4. The reasons for lack of gonad shield use by radiographers during diagnostic hip radiology of male patients require further study.

Conflicts of interest

We declare that we have no conflicts of interest.

References

1. Doolan A, Brennan CP, Rainford LA, et. al. Gonad protection for antero-posterior projection of the pelvis in diagnostic radiography in Dublin hospitals. Radiography 2004; 10(1): 15–21.
2. Fawcett SL, Barter SJ. The use of gonad shielding in pediatric hip and pelvis radiographs. BJR 2009; 82: 363–370.
3. Sikand M, Stinchcombe S, Livesley PJ. Study on the use of gonadal protection shields during paediatric pelvic X-rays. Ann R Coll Surg Engl 2003; 85: 422-425.
4. Bontrager KL, Lampignano JP. Radiographic positioning and related anatomy. Elsevier Mosby, Saint Louis 2010.
5. Statkiewicz-Sherer MS, Visconti PJ, Ritenour ER, Haynes K. Radiation protection in medical radiography. Elsevier MOSBY, Maryland 2014.
6. Whitley AS, Jefferson G, Holmes K, Sloane C, Anderson C, Hoadley G: Clarc's positioning in radiography. CRC Press Taylor & Francis Group, Boca Raton London New York 2015.
7. Tissue weighting factor [Internet]. European Nuclear Society [cited 26 Aug 2013]. Available from: http://www.euronuclear.org/info/encyclopedia/t/tissue-weight-factor.htm.
8. Wall BF, Haylock R, Jansen JMT, Hillier MC, Hart D. Radiation risk from medical X-ray examinations as a function of the age and sex of the patient. Chilton: Health Protection Agency Centre for Radiation, Chemical and Environmental Hazards. HPA-CRCE-028 2011.
9. Parry RA, Glaze SA, Archer BR. Typical patient radiation doses in diagnostic radiology. RadioGraphics 1999; 19: 1289-1302.
10. Rozporządzenie Ministra Zdrowia z 21 sierpnia 2006 roku w sprawie szczegółowych warunków bezpiecznej pracy z urządzeniami radiologicznymi (Dz. U. 2006.180.1325).
11. Obwieszczenie Ministra Zdrowia z dnia 10 listopada 2015 r. w sprawie ogłoszenia wykazu wzorcowych procedur radiologicznych z zakresu radiologii – diagnostyki obrazowej i radiologii zabiegowej (Dz. Urz. Min. Zdrow. 2015.78 z póź. zm.).
12. Stranden E, Andersen DA, Bergwitz-Larsen E, et. al. Main factors influencing the use of scrotum shields during X-ray examinations in major hospitals in Norway and Denmark. EJR 2009; 1(1): 7-11.
13. Behroozi H, Tahmasebi M, Mohebifar B. Evaluation of the prevalence of shielding in patients undergoing conventional radiological procedures (1 work shift-1 X-ray room). Journal of Patient Safety, 2015 DOI: 10.1097/PTS.0000000000000180.
14. Warlow T, Walker-Birch P, Cosson P. Gonad shielding in paediatric pelvic radiography: effectiveness and practice. Radiography 2014; 20(3): 178-182.
15. Frantzen MJ, Robben S, Postma AA, et. al. Gonad shielding in paediatric pelvic radiography: disadvantages prevail over benefit. Insights Imaging 2012: 3(1): 23-32.
16. Masud S, Mehra A, Clothier JC. Study on the use of gonadal shields in paediatric pelvic X-rays. J Bone Joint Surg 2008; 90-B(Suppl. II): 338.
17. Thomas GP. Basic radiographic procedures. The "GPT" methods [Internet]. [cited 2013 Aug 23] Available from: http://www.chiro.org/radiology/ABSTRACTS/ procedures.pdf
18. Leifke E, Gorenoi V, Wichwers C, et. al. Age related changes of serum sex hormones, IGF-1, and sex hormonem binding globulin levels in men: cross-sectional data from a healthy male cohort. Clin Endocrinol (Oxf) 2000; 53: 689-695.
19. MacKay M, Hancy C, Crowe A, et. al. Attitudes of medical imaging technologists on use of gonad shielding in general radiography. The Radiographer AIR 2012; 59(2): 35-39.
20. Rostamzadeh A, Farzizadeh M, Fatehi D. Evaluation of the level of protection in radiology departments of Kermanshah, Iran. IJMP 2015; 12(3): 200-208.
21. Stam W, Pillay M. Inspection of lead aprons: apractical rejection model. Health Phys. 2008; S2: 133-136 [Internet]. WRHA X-ray Safety Committee, X-ray safety manual 2013. [cited 2013 Aug 23] Available from: http://www.wrha.mb.ca/prog/diagnostic/files/ Manual_XRaySafety.pdf.
22. Ustawa z dnia 29 listopada 2000 r. Prawo atomowe (tekst jednolity Dz. U. 2014.1512 z póź. zm.).