

# Effects of botulinum toxin type A on masticatory muscle activity in patient with sleep bruxism – a case study

Michał Ginszt<sup>1</sup>, Grzegorz Michalczewski<sup>2</sup>,  
Marcin Berger<sup>2</sup>, Magdalena Bakalczuk<sup>3</sup>,  
Piotr Majcher<sup>1</sup>, Mansur Rahnama-Hezavah<sup>2</sup>

<sup>1</sup> Chair and Department of Rehabilitation, Physiotherapy and Balneotherapy, the Medical University of Lublin, Poland

<sup>2</sup> Chair and Department of Dental Surgery, Medical University of Lublin, Poland

<sup>3</sup> Department of Functional Masticatory Disorders, Medical University of Lublin, Poland

*European Journal of Medical Technologies* 2018; 2(19): 22-27

Copyright © 2018 by ISASDMT  
All rights reserved  
www.medical-technologies.eu  
Published online 14.08.2018

## Corresponding address:

Michał Ginszt  
Magnoliowa 2  
20-143 Lublin, Poland  
tel.+48602533723  
michalginszt@umlub.pl

## ABSTRACT

**Introduction:** Sleep bruxism, one of the common sleep-related movement disorders, occurs in 5% to 8% of the adult population. The findings from botulinum toxin studies are supportive of its effectiveness to reduce the intensity of sleep bruxism episodes.

**Aim:** The aim of this study was to investigate the effect of a botulinum toxin type A (BoNT-A) injection in the masseter muscle in the patient with diagnosed sleep bruxism and masticatory muscle pain using surface electromyography.

**Material and methods:** A case is reported of a 22-year-old woman who suffered from sleep bruxism and bilaterally masticatory muscle pain within masseter muscle. The BoNT-A (Azzalure®, Galderma SA) was injected into each masseter muscle (bilaterally) at a dose of 12 U (Speywood Units/ml) per muscle. Injections were performed at three points, one point in upper part of masseter muscle (6 U) and two points (3 U each) 1 cm apart at the center of the lower third of the masseter muscle. Electromyographic activity of the anterior temporalis (TA) and masseter muscle (MM) for right (R) and left side (L) was evaluated before (1) 15 minutes after the BTX-A injection (2) and after 3 weeks (3) in three conditions: during resting mandibular position, during maximum intercuspation

## Key words:

botulinum toxin type A, sEMG, masseter, sleep bruxism

clenching, and maximum voluntary clenching with cotton rolls between teeth. The 8-channel electromyograph BioEMG III, compatible with BioPAK Measurement System, was used for the recording.

**Results:** The masseter muscle activity during maximum intercuspatation clenching was reduced immediately and 3 weeks after BTX-A injection (MMR1: 183,4  $\mu$ V; MMR2: 98,6  $\mu$ V; MMR3: 17,1  $\mu$ V / MML1: 80,0  $\mu$ V; MML2: 43,4  $\mu$ V; MML3: 10,9  $\mu$ V). The masseter muscle activity during maximum voluntary clenching with cotton rolls between teeth was also reduced immediately and 3 weeks after BTX-A injection (MMR1: 140,0  $\mu$ V; MMR2: 95,0  $\mu$ V; MMR3: 17,6  $\mu$ V / MML1: 177,0  $\mu$ V; MML2: 88,0  $\mu$ V; MML3: 15,7  $\mu$ V).

**Conclusions:** Functional masseter muscle activity measured by sEMG was decreased immediately and 3 weeks after the botulinum toxin type A injection.

## Introduction

Sleep bruxism (SB), one of the common sleep-related movement disorders, occurs in 5% to 8% of the adult population [1]. SB is characterized by teeth grinding and clenching related to teeth destruction, pain in the teeth, jaw, masticatory muscle, and temporomandibular joint [2]. The etiology of sleep bruxism is uncertain. Several risk factors like tobacco smoking, alcohol, drugs, systemic diseases, stress, trauma, and heredity, appear to have an important role in the sleep bruxism genesis [3]. Moreover, the interaction between sleep and awake bruxism may increase the risk for masticatory muscles pain related to temporomandibular disorders [4]. Masticatory muscle pain and dysfunction, related to SB, can be caused by masticatory muscle hyperactivity [5,6]. However, electromyographic studies in patients with myofascial pain syndrome do not always show an increase in resting masticatory muscle activity [7].

Various treatment modalities such as an oral splint, pharmacological management, and behavioral approaches are effective for the management of SB. Although oral splint is the most commonly used treatment and considered as the first choice for protecting teeth from damages, current studies indicate high efficacy of pharmacological treatment in patients with bruxism [7,8]. Pharmacological therapies such as levodopa, clonidine, clonazepam,

and botulinum toxin type A (BoNT-A) was effective in decreasing the number of sleep-related masticatory parafunctions during bruxism events [7,9–11].

The findings from botulinum toxin studies are supportive of its effectiveness to reduce the intensity of sleep bruxism episodes [12]. The action of botulinum toxin is reversible. The effect of toxin occurs within 1–14 days, peaks at approximately 4 weeks and begins wearing off after 10–12 weeks [13]. Moreover, BoNT-A injection reduced the intensity of contractions for the masseter and temporalis muscles during sleep [7]. Hence the decrease of bruxism episodes associated with the use of BoNT-A may be related to the reduction of masticatory muscle activity [14]. It seems to be confirmed by animal studies, in which the masseter muscle activity of the rabbits was significantly reduced immediately after BoNT-A injection [15]. Similar results were observed in rats, in which masseter muscle activity decreased 99% during the first week after BoNT-A injection [16]. These observations were also confirmed in human studies, where a decrease in electromyographic parameters was also observed after the use of BoNT-A [17].

However, there are still only a few studies on changes in the bioelectrical activity of masticatory muscles due to the injection of botulinum toxin in patients with bruxism.

## Aim

The aim of this study was to investigate the effect of a botulinum toxin type A (BoNT-A) injection in the masseter muscle in the patient with diagnosed sleep bruxism and masticatory muscle pain using surface electromyography (sEMG).

## Materials and methods

### Ethics statement

This study was approved by the ethical committee of the Medical University of Lublin, Poland (KE-0254/331/2015). All patients were informed about the procedures they would undergo and gave their informed consent to participate in the tests.

### Subject description

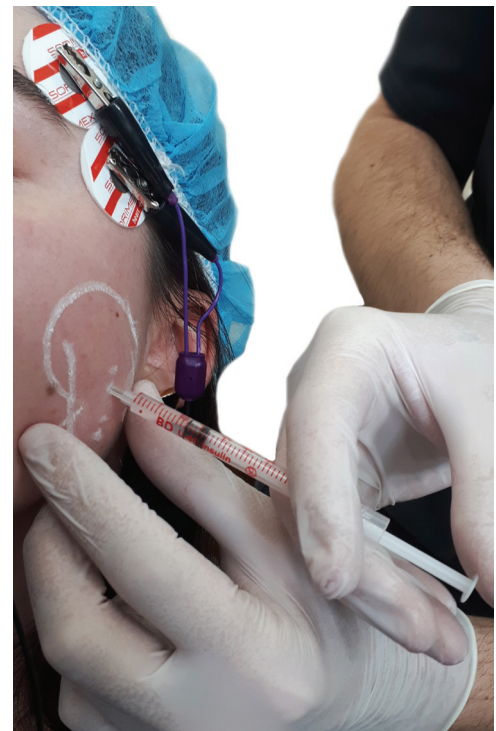
A case is reported of a 22-year-old woman who suffered from sleep bruxism and bilaterally masticatory muscle pain within masseter muscle. The patient has the manifestation of sleep bruxism and masseter muscle pain within the left and right side.

### Measurement plan

The measurement and the injection were made with the patient seated in a dental chair in an upright position. The BoNT-A (Azzalure®, Galderma SA) was injected into each masseter muscle (bilaterally) at a dose of 12 U (Speywood Units/ml) per muscle. Injections were performed at three points, one point in upper part of masseter muscle (6 U) and two points (3 U each) 1 cm apart at the center of the lower third of the masseter muscle as shown in Figure 1.

Prior to electrode placement, the skin was cleansed with 90% ethyl alcohol solution. The 8-channel electromyograph BioEMG III, compatible with BioPAK Measurement System, was used for the recording. The pairs of surface electrodes (Ag/AgCl) were distributed bilaterally on the anterior temporalis (TA) and masseter muscle (MM) as shown in Figure 2. For temporalis anterior, electrodes were distributed vertically along the anterior muscular margin, approximately over

the coronal suture. For masseter muscle, surface electrodes were placed at the intersection between the tragus-labial commissure and the exocanthion-gonion lines. The reference electrode was placed on the forehead. Electromyographic activity of the anterior temporalis and masseter muscles for right (R) and left side (L) was evaluated before injection (1), 15 minutes after the BTX-A injection (2), and



**Fig. 1.**  
Botulinum toxin injection



**Fig. 2.**  
The sEMG measurement

after 3 weeks (3) in three conditions: during resting mandibular position, during maximum intercuspation clenching, and maximum voluntary clenching with cotton rolls between teeth.

## Results

As presented in Table 1, anterior temporalis activity in resting mandibular position was reduced immediately after BTX-A injection and increased after 3 weeks. Masseter muscle activity in resting mandibular position was reduced immediately and 3 weeks after BTX-A injection (Table 1).

As presented in Table 2, the masseter muscle activity during maximum intercuspation clenching was reduced immediately and 3 weeks after

BTX-A injection ( $MM_{R1}$ : 183,4  $\mu$ V;  $MM_{R2}$ : 98,6  $\mu$ V;  $MM_{R3}$ : 17,1  $\mu$ V /  $MM_{L1}$ : 80,0  $\mu$ V;  $MM_{L2}$ : 43,4  $\mu$ V;  $MM_{L3}$ : 10,9  $\mu$ V). Anterior temporalis activity during maximum intercuspation clenching was reduced immediately after BTX-A injection, while after 3 weeks the activity was increased (Table 2).

The masseter muscle activity during maximum voluntary clenching with cotton rolls between teeth was also reduced immediately and 3 weeks after BTX-A injection ( $MM_{R1}$ : 140,0  $\mu$ V;  $MM_{R2}$ : 95,0  $\mu$ V;  $MM_{R3}$ : 17,6  $\mu$ V /  $MM_{L1}$ : 177,0  $\mu$ V;  $MM_{L2}$ : 88,0  $\mu$ V;  $MM_{L3}$ : 15,7  $\mu$ V). Anterior temporalis activity during maximum voluntary clenching with cotton rolls between teeth was reduced immediately after BTX-A injection, while after 3 weeks the activity was increased (Table 3).

**Table 1.**

sEMG activity of temporalis anterior (TA) and masseter muscles (MM) during resting mandibular position

Muscle	sEMG activity ( $\mu$ V)		
	Before	After 15 minutes	After 3 weeks
TA right	0.85	0.62	1.26
TA left	2.00	1.37	2.93
MM right	1.03	0.75	0.86
MM left	1.41	1.06	1.28

**Table 2.**

sEMG activity of temporalis anterior (TA) and masseter muscles (MM) during maximum intercuspation clenching

Muscle	sEMG activity ( $\mu$ V)		
	Before	After 15 minutes	After 3 weeks
TA right	114.6	81.1	118.4
TA left	94.6	53.9	112.8
MM right	183.4	98.6	17.1
MM left	80.0	43.4	10.9

**Table 3.**

sEMG activity of temporalis anterior (TA) and masseter muscles (MM) during maximum voluntary clenching with cotton rolls between teeth

Muscle	sEMG activity ( $\mu$ V)		
	Before	After 15 minutes	After 3 weeks
TA right	109.1	83.6	106.0
TA left	114.2	80.0	112.6
MM right	140.0	95.0	17.6
MM left	177.0	88.0	15.7

## Discussion

Several studies have been reported that botulinum toxin type A injections are effective for controlling involuntary orofacial movements during sleep bruxism episodes [7,9–11]. It is also worth noting that BoNT-A injections reduce the frequency of jaw motor events and decrease bruxism-induced pain levels [18]. However, just a few works concern changes in masticatory muscle activity in patients with bruxism treated with BoNT-A.

The aim of this study was to investigate the effect of a botulinum toxin type A injection in the masseter muscle in the patient with diagnosed sleep bruxism and masticatory muscle pain using surface electromyography. It was observed that functional masseter muscle activity measured by sEMG was decreased immediately and 3 weeks after the BoNT-A injection. The results of our study are in agreement with literature. The results of Zayed et al. study revealed a gradual and well-established decrease in muscular activity, which was statistically significant during the study period for masseter muscle [17]. Similar results were obtained by Shim et al. The BoNT-A injection decreased the peak amplitude of EMG burst of sleep bruxism episodes in masseter muscles [7]. In addition, Lee et al. reported that the number of EMG bruxism

events decreased after the botulinum toxin injection in the masseter muscle but not in the temporalis, which also seems to be in line with our observations [14].

However, in presented work, the activity of the masticatory muscles was examined during teeth clenching during the day. Thus, it remains unclear how BoNT-A injection works specifically for sleep-related masticatory EMG activity. Hence, research should be continued to investigate the activity of the masticatory muscles during sleep after treatment with BoNT-A.

## Conclusions

1. Functional masseter muscle activity measured by sEMG was decreased immediately and 3 weeks after the botulinum toxin type A injection.

## Acknowledgments

The results of the present study do not constitute an endorsement of the product by the authors or the journal.

## Conflict of interest

The authors declare that they have no conflict of interest.

## REFERENCES

1. Kato T, Velly AM, Nakane T, Masuda Y, Maki S. Age is associated with self-reported sleep bruxism, independently of tooth loss. *Sleep Breath Schlaf Atm.* 2012;16(4):1159–65.
2. Carra MC, Huynh N, Lavigne G. Sleep bruxism: a comprehensive overview for the dental clinician interested in sleep medicine. *Dent Clin North Am.* 2012;56(2):387–413.
3. Cuccia AM. Etiology of sleep bruxism: a review of the literature. *Recenti Prog Med.* 2008;99(6):322–8.
4. Berger M, Szalewski L, Szkutnik J, Ginszt M, Ginszt A. Different association between specific manifestations of bruxism and temporomandibular disorder pain. *Neurol Neurochir Pol.* 2017;51(1):7–11.
5. Rodrigues D, Siriani AO, Bérzin F. Effect of conventional TENS on pain and electromyographic activity of masticatory muscles in TMD patients. *Braz Oral Res.* 2004;18(4):290–5.
6. Ueda HM, Kato M, Saifuddin M, Tabe H, Yamaguchi K, Tanne K. Differences in the fatigue of masticatory and neck muscles between male and female. *J Oral Rehabil.* 2002;29(6):575–82.
7. Shim YJ, Lee MK, Kato T, Park HU, Heo K, Kim ST. Effects of botulinum toxin on jaw motor events during sleep in sleep bruxism patients: a polysomnographic evaluation. *J Clin Sleep Med JCSM Off Publ Am Acad Sleep Med.* 2014;10(3):291–8.
8. Guaita M, Högl B. Current Treatments of Bruxism. *Curr Treat Options Neurol.* 2016;18(2):10
9. Lobbezoo F, Lavigne GJ, Tanguay R, Montplaisir JY. The effect of catecholamine precursor L-dopa on sleep bruxism: a controlled clinical trial. *Mov Disord Off J Mov Disord Soc.* 1997;12(1):73–8.
10. Huynh N, Lavigne GJ, Lanfranchi PA, Montplaisir JY, de Champlain J. The effect of 2 sympatholytic medications – propranolol and clonidine – on sleep bruxism: experimental randomized controlled studies. *Sleep.* 2006;29(3):307–16.
11. Saletu A, Parapatics S, Anderer P, Matejka M, Saletu B. Controlled clinical, polysomnographic and psychometric studies on differences between sleep bruxers and controls and acute effects of clonazepam as compared with placebo. *Eur Arch Psychiatry Clin Neurosci.* 2010;260(2):163–74.
12. Manfredini D, Ahlberg J, Winocur E, Lobbezoo F. Management of sleep bruxism in adults: a qualitative systematic literature review. *J Oral Rehabil.* 2015;42(11):862–74.
13. Sunil Dutt C, Ramnani P, Thakur D, Pandit M. Botulinum Toxin in the Treatment of Muscle Specific Oro-Facial Pain: A Literature Review. *J Maxillofac Oral Surg.* 2015;14(2):171–5.
14. Lee SJ, McCall WD, Kim YK, Chung SC, Chung JW. Effect of botulinum toxin injection on nocturnal bruxism: a randomized controlled trial. *Am J Phys Med Rehabil.* 2010;89(1):16–23.
15. Park S-Y, Park Y-W, Ji Y-J, Park S-W, Kim S-G. Effects of a botulinum toxin type A injection on the masseter muscle: An animal model study. *Maxillofac Plast Reconstr Surg.* 2015; 37(1):10.
16. Tsai CY, Lei YY, Yang LY, Chiu WC. Changes of masseter muscle activity following injection of botulinum toxin type A in adult rats. *Orthod Craniofac Res.* 18(4):202–11.
17. Zayed OM, Khedr MMS, Sadakah AAM, El-deeb AE. Evaluation of using botulinum toxin (A) in the treatment of myofacial pain syndrome. *Tanta Dent J.* 2015;12(3):156–62.
18. Guarda-Nardini L, Manfredini D, Salamone M, Salmaso L, Tonello S, Ferronato G. Efficacy of botulinum toxin in treating myofascial pain in bruxers: a controlled placebo pilot study. *Cranio J Cranio-mandib Pract.* 2008;26(2):126–35.