

Multielectrode mapping catheters- an indispensable tool for cardiac ablation strategy guidance

Przemysław Zajac¹, Bartosz Małachowski¹, Natalia Zajac², Karolina Wójcik³, Łukasz Konarski⁴, Maciej Wójcik⁴

¹ Abbott Medical Poland

² Independent Provincial Public Hospital in Zamość, Poland

³ Student, Medical University of Lublin, Poland

⁴ Department of Cardiology, Medical University of Lublin, Poland

European Journal of Medical Technologies

2018; 2(19): 28-35

Copyright © 2018 by ISASDMT
All rights reserved

www.medical-technologies.eu
Published online 14.08.2018

Corresponding address:

dr hab. n. med.

Maciej Wójcik

Department of Cardiology,

Medical University

of Lublin, Poland

SPSK Nr 4, ul.

Jaczeńskiego 8

20-954 Lublin, Poland

e-mail: m.wojcik@

am.lublin.pl

Abstract

Radiofrequency catheter ablation is a proved interventional approach used for treatment of various cardiac arrhythmias. Although, radiofrequency ablation is indicated by a distinctive success rate, understanding some of arrhythmias remains challenging. Especially, substrate-based approach requires an accurate and detailed identification of scar or slow conducting areas, that can be visualized as high-density maps performed with multielectrode catheters. Arrhythmogenic tissue targeting and ablation strategy guidance are feasible by high-density mapping and offers the possibility of improving patient quality of life.

Key words:

multielectrode catheter, cardiac ablation, substrate mapping, cardiology, electrophysiology, heart, arrhythmia

Introduction

Throughout last two decades, cardiac rhythm treatment has evolved significantly [1,2]. Currently, the most widely spread interventional approach used for interventional treatment of cardiac arrhythmias is catheter ablation. The abnormal tissue, responsible for the discordant cardiac conduction, is heated up and destroyed due to delivered radio frequency (RF) current [3]. In the 90s, parallelly with deeper medical understanding of arrhythmia mechanisms, more advanced technology was brought into this field. With the assistance of recording and three-dimensional (3D) electroanatomic mapping systems (EMS), via offering multiple functions (e.g. activation and voltage mapping), arrhythmogenic tissue targeting and guidance the ablation strategy, has become more efficient and effective [4].

Although RF ablation showed a distinctive success rate [5-7], understanding some of arrhythmias remained challenging, especially post-ablation atrial tachycardias (AT) [8-10] or ventricular tachycardias (VT) [11-13].

Prevalence of the AT is associated with complex fractionated atrial electrograms (CFAEs) and additional lines (e.g. roof line, mitral isthmus line, anterior line) performed above standard pulmonary vein isolation (PVI) during atrial fibrillation (AF) ablation. Gaps along the lines may potentially play a role in arrhythmia occurrence as a part of the re-entry circuit [14]. Moreover, specific tissue properties, identified by fractionated electrograms [15], and a heterogeneous atrial substrate [16], are associated with AF sustainment, so considering AF, PVI alone is less effective and additional substrate ablation is frequently performed [17-19]. Combination of anatomical and electrical data of the tissue helps to identify arrhythmia mechanism and can be used for individual patient therapy approach [20].

In treatment of structural heart disease the detailed knowledge of the VT substrate is mandatory to identify the potential VT circuits [21]. VT ablation procedures are technically challenging with a non-negligible risk of complications [22-24], usually associated with long ablation time due to the presence of multiple VT circuits or extend substrate [25,26]

that can be identified and targeted during voltage mapping [27-29] or by analyzing the activation sequence of the delayed local component of abnormal electrograms (EGMs) within the scar region [30,31]. The identification of scar, may be based on bipolar or/and unipolar voltage mapping [32,33]. Ablation of arrhythmogenic substrate is an effective ablation strategy for patients with noninducible or hemodynamically poorly tolerated VT [34,35] and offers the possibility of improving patient quality of life, reducing mortality as well as painful defibrillator interventions and heart failure hospitalizations [36-38].

Current substrate ablation strategies aim to completely abolition of abnormal EGMs [39-41]. Therefore, substrate-based approach requires an accurate and detailed identification of scar or slow conducting areas, which can be visualized as high-density maps performed with multielectrode catheters [42,43]

Substrate mapping strategies rely on point-by-point signals acquisition to identify ablation targets, predominantly performed using 4-poles linear ablation catheter with typical distal electrode size of 3.5-4 mm. Electrodes spacing varies from 2 to 2.5 and proximal electrodes are 1-2 mm long [44,45].

Bipolar EGMs, obtained by these type of catheters, represent the electrical activity from an underlying tissue area ranging from 1 to 2.4 cm² [46]. Catheters with 1 mm electrodes, 2 mm interelectrode spacing and 3 mm center-to-center interelectrode distance, record EGMs from a smaller field, dependent on catheter orientation [47].

Although, point-by-point mapping is time consuming and is associated with prolonged procedure time, these catheters have been widely exploited during last years [44].

Multielectrode mapping catheters

Promising alternative for conventional point-by-point mapping are multielectrode catheters. Smaller electrodes with closer interelectrode spacing of multielectrode catheters, led to higher mapping resolution that can identify heterogeneity within the low-voltage area [34], localizing channels of surviving

bundles [17], allowing more accurate time annotation [18] due to screening signals from a smaller tissue area. Through the features of multielectrode catheters the effectiveness of the ablation may be increased and procedure time is shortened what is extremely important in patients who are in unstable hemodynamic conditions [44].

Initially, the plain multielectrode catheters have been used for high-density mapping, especially during substrate guided left ventricular tachycardias (Fig. 1) in both, endo- and epicardial arrhythmogenic tissue localization [48]. These catheters (e.g. Livewire™ Duo-Deca, Abbott) are characterized by soft shaft, particularly important in retrograde (transaortal) access, and multitude narrow electrodes with small interelectrode distance.

The circular multielectrode catheters (e.g. Advisor™ FL SE™, Abbott) (Fig. 2) are widely used during AF ablation procedures at different levels: firstly, for fast anatomical mapping and 3D model creation [49]; secondly, for voltage scanning to identify atrial fibrotic regions [50]; thirdly, for confirmation of pulmonary veins electrical isolation [51]; fourthly, for activation mapping when AF terminates and converts into AT [52] (Fig. 3. A-D).

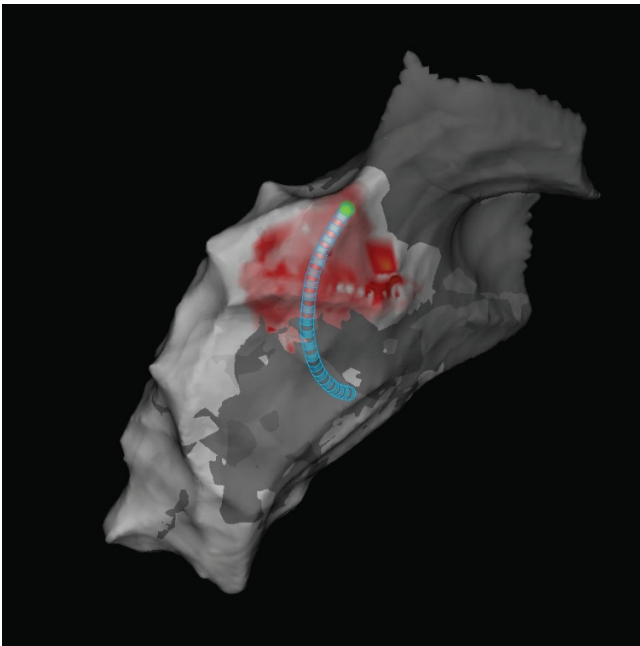


Fig. 1.

Activation map presenting late-diastolic activity (red area) performed with the plain multielectrode catheter (Livewire™ Duo-Deca) visualized by electroanatomic mapping system (EnSite Precision™)

Circular uni- or bidirectional mapping catheters consist of the multielectrode (ten or twenty) fixed or variable loop that facilitates collection of anatomical and electrical pulmonary veins characteristics, i.e. diagnose reconnection, estimate the reconnection site, and check the isolation after ablation [53].

Another tool that can facilitate atrial and ventricular mapping is a PentaRay® (Biosense Webster). This star-shaped 20-pole catheter is composed of five flexible 3F branches, with four small 1 mm electrodes located within each of them, allowing high resolution and density mapping. PentaRay® is used in conjunction with Carto® (Biosense Webster) EMS to create a three-dimensional reconstruction.

With all advantages of using PentaRay® catheter, its potential disadvantage is the mechanical induction of premature beats that could degenerate into ventricular fibrillation [54].

Apart from more traditional catheters as linear, circular or star-shaped catheters, the mapping deployment basket (IntellaMap Orion™, Boston Scientific) has been developed to rapidly obtain a high resolution electroanatomic map. This 8F irrigated catheter has a 64-electrode basket array divided in eight splines with 2.5 mm interelectrode spacing. Mapping can be performed from all electrodes simultaneously. The basket localization is identified by a combination of a magnetic and an impedance sensing and can be visualize by Rhythmia™ (Boston Scientific) electroanatomic 3D system [55].



Fig. 2.

Advisor™ FL SE™ - circular multielectrode mapping catheter

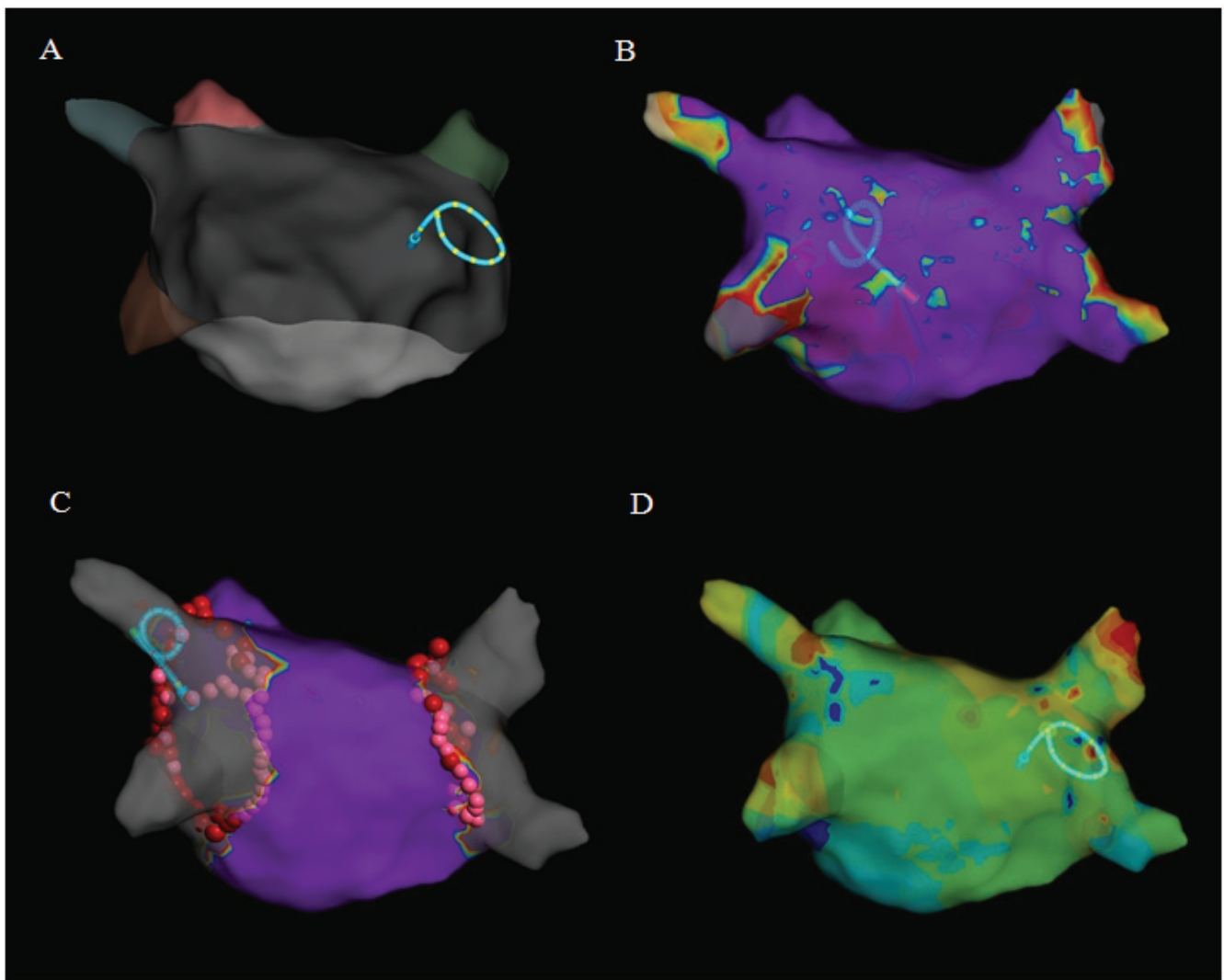


Fig. 3.

Different usage of the circular multi-electrode catheter (Advisor™ FL SE™) visualized by electroanatomic mapping system (EnSite Precision™). A: anatomical mapping (3D model of left atrium). B: voltage mapping (purple area- healthy tissue, grey area- scar or non-conductive tissue, red/yellow/blue- low voltage area). C: electrical pulmonary vein isolation (represented by grey color) confirmation. D: activation mapping (different colors represent circuit activity – white/red – early; cyan/blue – late)

Basket-type multi-electrode catheters can be used to verify and anatomically identify conduction gaps by an analysis of the signals and activation map [56].

The most recent mapping catheter, still limitedly released on the market, is Advisor™ HD Grid SE™ (Abbott) (Fig. 4) intended to acquire atrial and ventricular electrograms. The 18-electrode irrigated catheter has been design with equidistant (3-3-3) electrode spacing. Unique four-spline shape of the mapping end allowing

for recording signals along and across the spline dependently on activation wave directionality. This concept leads to reduction in variability in EGMs characteristics associated with differential orientation of the catheter relative to the propagating wavefront [57].

In conjunction with EnSite Precision™ EMS, comparing parallel and perpendicular activation towards electrodes, only the highest amplitude data is collected and displayed on the map (Fig. 5) [58].




Fig. 4. Advisor™ HD Grid SE™ – multielectrode mapping catheter

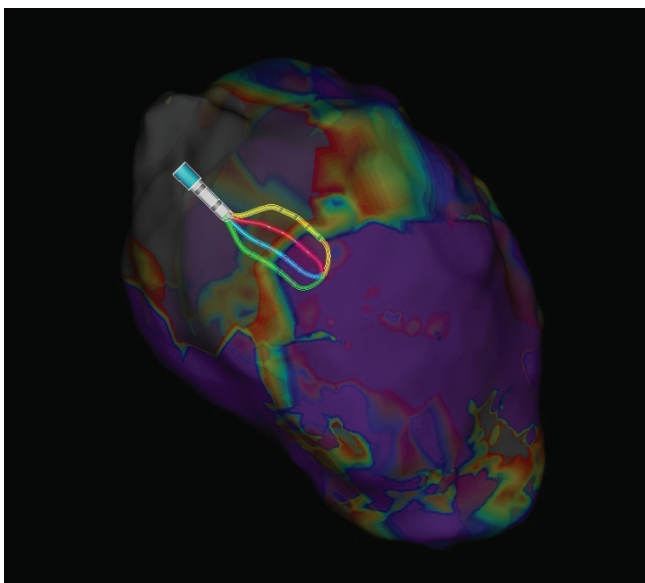


Fig. 5. High-density bipolar voltage map (purple area – healthy tissue, grey area – scar, red/yellow/blue – low voltage area) performed with Advisor™ HD Grid SE™ multielectrode catheter visualized by electroanatomic mapping system (EnSite Precision™)

Conclusions

Huge progress in the medical technology, observed in the last years, led to development of new high-density diagnostic catheters. Multipolar catheters with smaller electrodes and shorter interelectrode distances represent more effective tools for high-density mapping than conventional catheters used so far. Still, such catheters do not have a contact force sensing technology, which could result in the acquisition of internal points and can artificially produce a low-voltage area.

References

1. Anselmino M, Sillano D, Casolati D, Ferraris F, Scaglione M, Gaita F. A new electrophysiology era: zero fluoroscopy. *J Cardiovasc Med (Hagerstown)* 2013; 14: 221-227.
2. Gaita F, Guerra P, Battaglia A, Anselmino M. The dream of near-zero X-rays ablation comes true. *European Heart Journal* 2016; 37, 2746-2755.
3. Haines E.D. The biophysics of radiofrequency catheter ablation in the heart: the importance of temperature monitoring. *PACE* 1993; 16: 586-591.
4. Zając P, Rycyk M, Pić N, Wójcik K, Konarski Ł, Wójcik M. Electroanatomic Mapping System – the useful tool for electrophysiology. *European Journal of Medical Technologies* 2016; 4 (13): 17-26.
5. Ayabakan C, Sahin M, Celikier A. Radiofrequency catheter ablation of left-sided accessory pathways via retrograde aortic approach in children. *J Arrhythm.* 2016; 32 (3): 176-80.
6. Stabile G, Di Donna P, Schillaci V, Di Monaco A, Juliano A, et al. Safety and efficacy of pulmonary vein isolation using a surround flow catheter with contact force measurement capabilities: a multi-center registry. *J Cardiovasc Electrophysiol.* 2017; 28 (7): 762-767.
7. Berruezo A, Acosta J, Fernandez-Armenta J, Pedrote A, Barrera A, et al. Safety, long-term outcomes and predictors of recurrence after first-line combined endoepicardial ventricular tachycardia substrate ablation in arrhythmogenic cardiomyopathy. Impact of arrhythmic substrate distribution pattern. A prospective multicenter study. *Europace* 2017; 19 (4): 607-616.
8. Coffey JO, d'Avilla A, Dukkipati S, Danik SB, Gangireddy SR, et al. Catheter ablation of scar-related atypical flutter. *Europace* 2013; 15 (3): 414-9.
9. Roca-Lugue I, Rivas-Gandara N, Dos-Subira L, Francisco-Pascual J, Pijuan-Domenech A, et al. Predictors of acute failure ablation of intra-atrial re-entrant tachycardia in patients with congenital heart disease: cardiac disease, atypical flutter, and previous atrial fibrillation. *J Am Heart Assoc.* 2018; 7 (7).
10. Cosio FG. Atrial flutter, typical and atypical: a review. *Arrhythm Electrophysiol Rev.* 2017; 6 (2): 55-62.
11. Banavalikar B, Shenthathar J. Electrocardiographic characteristics and mapping approach of

- ventricular arrhythmias originating from the left ventricular summit. *J Electrocardiol.* 2018; 51 (4): 687-690.
12. Dallet C, Roney CH, Martin R, Kitamura T, Puyo S, et al. Cardiac propagation pattern mapping with vector field for helping tachyarrhythmias diagnosis with clinical tridimensional electro-anatomical mapping tools. *IEEE Trans Biomed Eng.* 2018.
 13. Miyamoto K, Matsuyama TA, Noda T, Ishibashi-Uheda H, Kusano K. Pathology after a combination of sequential and simultaneous unipolar radiofrequency ablation of ventricular tachycardia in a postmortem heart with cardiac sarcoidosis. *Clin Case Rep.* 2018; 6 (7): 1219-1224.
 14. Andrade JG, Macle L, Khairy P, Khaykin Ym Mantovan R, De Martino G, et al. Incidence and significance of early recurrences associated with different ablation strategies for AF: a STAR-AF sub-study. *J Cardiovasc Electrophysiol.* 2012; 23 (12): 1295-301.
 15. Nademanee K, McKenzie J, Kosar E, Schwab M, Sunsaneewitayakul B, et al. A new approach for catheter ablation of atrial fibrillation: mapping of the electrophysiologic substrate. *J Amer Coll Cardiol.* 2004; 43 (11): 2044-53.
 16. Williams SE, Linton N, O'Neill L, Harrison J, Whitaker J, et al. The effect of activation rate on left atrial bipolar voltage in patents with paroxysmal atrial fibrillation. *J Cardiovasc Electrophysiol.* 2017; 28 (9): 1028-1036.
 17. Bhargava M, Di Biase L, Mohanty P, Prasad S, Martin DO, et al. Impact of type of atrial fibrillation and repeat catheter ablation on long-term freedom from atrial fibrillation: results from a multicenter study. *Heart Rhythm.* 2009; 6: 1403-1412.
 18. Tzou WS, Marchlinski FE, Zado ES, Lin D, Dixit S, et al. Long-term outcome after successful catheter ablation of atrial fibrillation. *Circ Arrhythm Electrophysiol.* 2010; 3: 237-242.
 19. Wójcik M, Konarski Ł, Błaszczuk R, Aljabali P, Zajac P. High-density bipolar voltage mapping for substrate-guided ablation of atrial fibrillation. *Kardiologia Polska.* 2018; 76 (7): 1115.
 20. Aslandi OV, Colman MA, Stott J, Dobrzyński H, Boyett MR, et al. 3D virtual human atria: a computational platform for studying clinical atrial fibrillation. *Progress in Biophysics and Molecular Biology.* 2011; 107 (1): 156-168.
 21. Wójcik M, Konarski Ł, Aljabali P, Zajac P, Błaszczuk R. Ablation of symptomatic ventricular tachycardia after surgical correction of ventricular septal defect in childhood: using high-density mapping, how precise is EnSite Precision? *Kardiologia Polska.* 2018; 76 (5): 930.
 22. Peichl P, Wichterle D, Pavlu L, Cihak R, Aldhoon B, Kautzner J. Complications of catheter ablation of ventricular tachycardia: a single-center experience. *Circ Arrhythm Electrophysiol.* 2014; 7: 684-690.
 23. Katz DF, Turakhia MP, Sauer WH, et al. Safety of ventricular tachycardia ablation in clinical practice: Findings from 9699 hospital discharge records. *Circ Arrhythm Electrophysiol.* 2015; 8: 362-370.
 24. Palaniswamy C, Kolte D, Harikrishnan P, et al. Catheter ablation of postinfarction ventricular tachycardia. Ten-year trends in utilization, in-hospital complications, and in-hospital mortality in the United States. *Heart Rhythm.* 2014; 11:2056-2063.
 25. Gokoglan Y, Mohanty S, Gianni C, et al. Scar homogenization versus limited-substrate ablation in patients with nonischemic cardiomyopathy and ventricular tachycardia. *J Am Coll Cardiol.* 2016; 68: 1990-1998.
 26. Di Biase L, Burkhardt JD, Lakkireddy D, et al. Ablation of stable VTs versus substrate ablation in ischemic cardiomyopathy: the VISTA randomized multicenter trial. *J Am Coll Cardiol.* 2015; 66: 2872-2882.
 27. Arenal A, del Castillo S, Gonzalez-Torrecilla E, Atienza F, Ortiz M, et al. Tachycardia-related channel in the scar tissue in patients with sustained monomorphic ventricular tachycardias: influence of the voltage scar definition. *Circulation.* 2004; 110: 2568-74.
 28. Hsia HH, Lin D, Sauer WH, Callans DJ, Marchlinski FE. Anatomic characterization of endocardial substrate for hemodynamically stable reentrant ventricular tachycardia: indetyfication of endocardial conducting channels. *Heart Rhythm* 2006; 3: 503-512.
 29. Andreu D, Ortiz-Perez JT, Fernandez-Armenta J, Guiu E, Acosta J, et al. 3D delayed-enhanced magnetic resonance sequences improve conducting channel delineation prior to ventricular tachycardia ablation. *Europace.* 2015; 17: 938-45.
 30. Fernandez-Armeta J, Andreu D, Penela D, Truc-co E, Cippolletta L, et al. Sinus rhythm detection of conducting channels and ventricular tachycardia

- isthmus in arrhythmogenic right ventricular cardiomyopathy. *Heart Rhythm*. 2014; 11: 747-54.
31. Tung R, Mathuria NS, Nagel R, Mandapati R, Buch EF, et al. Impact of local ablation on interconnected channels within ventricular scar: mechanistic implications for substrate modification. *Circ Arrhythm Electrophysiol* 2013; 6: 1131-8.
 32. Cano O, Hutchinson M, Lin D, Garcia F, Zado E, Bet al. Electroanatomic substrate and ablation outcome for suspected epicardial ventricular tachycardia in left ventricular nonischemic cardiomyopathy. *J Am Coll Cardiol*. 2009; 54: 799-808.
 33. Piers SR, van Huls van Taxis CF, Tao Q, vander Geest RJ, et al. Epicardial substrate mapping for ventricular tachycardia ablation in patients with non-ischemic cardiomyopathy: a new algorithm to differentiate between scar and viable myocardium developed by simultaneous integration of computed tomography and contrast-enhanced magnetic resonance imaging. *Eur Heart J*. 2013; 34: 586-596.
 34. Aliot EM, Stevenson WG, Almendral-Garrote JM, Bogun F, Calkins CH, et al, European Heart Rhythm Association, European Society of Cardiology, Heart Rhythm Society: EHRA/HRS Expert Consensus on Catheter Ablation of Ventricular Arrhythmias: Developed in partnership with the European Heart Rhythm Association (EHRA), a Registered Branch of the European Society of Cardiology (ESC), and the Heart Rhythm Society (HRS); in collaboration with the American College of Cardiology (ACC) and the American Heart Association (AHA). *Europace*. 2009; 11: 771-817.
 35. Natale A, Raviele A, Al-Ahmad A, Alfieri O, Aliot E, et al., Venice Chart members: Venice Chart International Consensus document on ventricular tachycardia/ventricular fibrillation ablation. *J Cardiovasc Electrophysiol*. 2010; 21: 339-379.
 36. Poole JE, Johnson GW, Hellkamp AS, Anderson J, Callans DJ, Raitt MH, Reddy RK, et al. Prognostic importance of defibrillator shocks in patients with heart failure. *N Engl J Med*. 2008; 359 (10): 1009-1017.
 37. Dinov B, Fiedler L, Schonbauer R, Bollmann A, Rolf S, et al. Outcomes in catheter ablation of ventricular tachycardia in dilated nonischemic cardiomyopathy compared with ischemic ischemic cardiomyopathy: results from the Prospective Heart Centre of Leipzig VT (HELP-VT) Study. *Circulation*. 2014; 129 (7): 728-736.
 38. Santangeli P, Frankel DS, Marchlinski FE, End points for ablation of scar-related ventricular tachycardia. *Circ Arrhythm Electrophysiol*. 2014; 7 (5): 949-960.
 39. Jais P, Maury P, Khairy P, Sacher F, Nault I, et al. Elimination of local abnormal ventricular activities: a new end point for substrate modification in patients with scar-related ventricular tachycardia. *Circulation*. 2012; 125: 2184-96.
 40. Di Biase L, Santangeli P, Burkhardt DJ, Bai R, Mohanty P, et al. Endo-epicardial homogenization of the scar versus limited substrate ablation for the treatment of electrical storms in patients with ischemic cardiomyopathy. *J Am Coll Cardiol*. 2012; 60: 132-41.
 41. Berruezo A, Fernandez-Armenta J, Andreu D, Penela D, Herczku C, et al. Scar dechanneling: a new method for scar-related left ventricular tachycardia substrate ablation. *Circ Arrhythm Electrophysiol*. 2015; 8: 326-36.
 42. Berte B, Relan J, Sacher F, Pillois X, Appetiti A, et al. Impact of electrode type on mapping of scar-related VT. *J Cardiovasc Electrophysiol*. 2015; 26: 1213-1223.
 43. Berruezo A, Fernandez-Armenta J, Lines, circles, channels and clouds: looking for the best design for substrate-guided ablation of ventricular tachycardia. *Europace*. 2014; 16: 943-5.
 44. Cano O, Plaza D, Sauri A, Osca J, Alonso P, et al. Utility of high density multielectrode mapping during ablation of scar-related ventricular tachycardia. *J Cardiovasc Electrophysiol*. 2017; 28: 1306-1315.
 45. Berte B, Relan J, Sacher F, Pillois X, Appetti A, et al. Impact of electrode type on mapping of scar-related VT. *J Cardiovasc Electrophysiol*. 2015; 26 (11): 1213-1223.
 46. Stinnett-Donnelly JM, Thompson N, Habel N, Petrov-Kondratov V, Correa de Sa DD, et al. Effects of electrode size and spacing on the resolution of intracardiac electrograms. *Coronary Artery Dis*. 2012; 23: 126-32.
 47. Anter E, Tschabrunn CM, Jodsephson ME. High-resolution mapping of scar-related atrial arrhythmias using smaller electrodes with closer interelectrode spacing. *Circ Arrhythm Electrophysiol*. 2015; 8: 537-545.

48. Vergara P, Rogue C, Oloriz T, Mazzone P, Della Bella P. Substrate mapping strategies for successful ablation of ventricular tachycardia: a review. *Arch Cardiol Mex.* 2013; 83 (2): 104-11.
49. Koruth JS, Heist EK, Danik S, Barrett CD, Kabra R, et al. Accuracy of left atrial anatomical maps acquired with a multielectrode catheter during catheter ablation for atrial fibrillation. *J Interv Card Electrophysiol.* 2011; 32: 45-51.
50. Kottkamp H, Bender R, Berg J. Catheter ablation of atrial fibrillation: how to modify the substrate? *J Am Coll Cardiol.* 2015; 65: 196-206.
51. Reinsch N, Buchholz J, Ruprecht U, Neven K. Entrapment of a circular mapping catheter in a pulmonary vein during atrial fibrillation. *J Interv Card Electrophysiol.* 2018; 7.
52. Patel AM, d'Avila A, Neuzil P, Kim SJ, Mela T, et al. Atrial tachycardia after ablation of persistent atrial fibrillation: identification of the critical isthmus with a combination of multielectrode activation mapping and targeted entrainment mapping. *Circ Arrhythm Electrophysiol.* 2008; 1: 14-22.
53. Garcia-Bolao I, Ballesteros G, Ramos P, Menendez D, Erkiaga A, et al. Identification of pulmonary vein reconnection gaps with high-density mapping in redo atrial fibrillation ablation procedures. *Europace.* 2017; 0: 1-8.
54. Acosta J, Panella D, Andreu D, Cabrera M, Carlosena A, et al. Multielectrode vs. point-by-point mapping for ventricular tachycardia substrate ablation: a randomized study. *Europace.* 2018; 20: 512-519.
55. Nakagawa H, Ikeda A, Sharma T, Lazzara R, Jackman WM. Rapid high resolution electroanatomical mapping: evaluation of a new system in a canine atrial linear lesion model. *Circ Arrhythm Electrophysiol.* 2012; 5: 417-24.
56. Bollmann A, Kosiuk J, Hilbert S, John S, Hindricks G. Percutaneous transapical access for pulmonary vein mapping and ablation in a porcine model with a new high-density electroanatomical mapping system. *Int J C Exp Med.* 2015; 8 (8): 12631-12636.
57. Takigawa M, Relan J, Martin R, Kim S, Kitamura T, et al. The importance of bipolar electrode orientation on local electrogram properties. *Heart Rhythm.* 2018 Jul 16.
58. Zając P, Konarski Ł, Wójcik M. EnSite Precision™-3D cardiac mapping system. *European Journal of Medical Technologies.* 2016; 3 (12): 1-7.