The concept of prosthetic restoration based on implants with retention resulting both from screwing and cementing – clinical case report

Andrzej Bożyk[1], Grzegorz Michalczewski[1], Leszek Szalewski[1], Agata Niewczas[2], Krzysztof Kruszyński[3], Magdalena Bakalczuk[4], Weronika Pucek[5]

[1] Department of Dental Prosthetics of Medical University of Lublin, Poland

[2] Chair and Department of Conservative Dentistry with Endodonthic of Medical, Lublin, Poland

[3] Kadent System, Rzeszów, Poland

[4] Department of Functional Masticatory Disorders of Medical University of Lublin, Poland

[5] Scientific Society at the Laboratory of Diagnostic Techniques of Faculty of Nursing and Health Sciences, Medical University of Lublin, Poland

European Journal of Medical Technologies
2016; 1(10): 8-14

www. medical-technologies.eu
Published online 22.03.2016
7.00 scores MNiSW

Corresponding address:
Andrzej Bożyk
Department of Dental Prosthetics of Medical University of Lublin
ul. Karmelicka 7
20-081 Lublin
drandrzejbozyk@gmail.com

Summary

The aim of the study was to present the prosthetic restoration combining the features of both screw-retained and cement-retained reconstruction. The authors made an attempt to link advantages of both types of construction. The presented concept eliminates the lack of passivity arising at the stage of casting the metal structure. The technique is applicable in the case of using a large number of implants (over 4) connected together into a non-removable structure with the absence of parallelism of intra-osseous implants. The whole structure ensures large passivity (flexible operation of temporary cement) and the possibility of removal, e.g. for hygenisation. This concept is also cheaper than the CAD/CAM technology.

Key words:

fixed bridge, implants, dental cements

Introduction

Over the years, the use of fixed dentures has required the pillars of the patient's natural teeth. In the case of the many interdental defects or missing posterior teeth the patient was doomed to removable dentures: tooth supported or tissue/tooth supported. Since the fifties of the previous century thanks to the work of professor Branemark and co-workers it has been possible to use intra-osseous implants in such cases.

At present, permanent prosthetic restorations based on implants are very often used, and the effectiveness of such solutions is thoroughly investigated and confirmed [1,2]. Five-year long observations have shown that 95% of restorations have properly fulfilled their functions [2]. Obviously the success of prosthetic work is not only the result from properly performed implantation procedure, very important are also the proper selection, design and fabrication of the prosthetic restoration.

In the case of fixed dentures embedded on implants their retention may result from being cemented or these can be restorations screwed to intra-osseous implants. Initially implant-bridges were by choice screwed restorations [3,4], while single crowns were cemented [5]. Currently, every restoration can be mounted in two ways depending on the anatomical, functional and aesthetic conditions. Both methods have their advantages and disadvantages.

The clinical and laboratory stages of making cement-retained restorations are similar to making fixed bridges on the patient's own teeth. CAD/CAM systems allow the fabrication of individual connecting elements, thanks to which in many cases this method is treated as a method by choice. A big problem in the case of cement-retained restorations is the possibility of leaving residues of cement around the implant. The residual material is very often the cause of inflammation of tissues around the implant. In *in vitro* examination Linkevicius and co-workers observed remnants of not removed cement in each sample [6]. The residual fragments of bonding material can easily give rise to periimplantitis [7]. Another disadvantage of cement-retained restorations is the fact that it is very difficult or almost impossible to remove the restoration in the case of any complications which may include loosening of the screw clamping the connecting element or a loss of a piece of veneer material. However, the possibility to accurately model the masticatory surface must be emphasized as an advantage. In screw-retained restorations the screw hole should be disguised, mostly frequently by means of composite materials and the relief of the occlusal surface needs to be restored. Cement-retained restorations, due to the thin layer of connecting material, have a margin of compensation of errors resulting from the fact of laboratory execution or clinical aspects.

On the other hand, screw-retained restorations are relatively easy to remove and re-attach on the implant. In addition, in the literature we can find reports indicating that complications in the case of screw-retained restorations are very rare [8]. If the restoration is to comply to the rules of aesthetics, the holes of connecting screws must be located in invisible places. In some clinical cases because of the need to use angular connectors which impose the location of the access hole on the labial surface, the use of screw-retained restorations is not recommended. Moreover, cases of a loss of the connecting screw and porcelain chipping around the location of the connection have been recorded [9]. In addition, laboratory stages of screw-retained restoration fabrication are more complicated than in the case of cement restorations. Another relevant aspect are micro-leaks occurring in screw-retained restorations which are conductive to the accumulation of biofilm on the line of the masticatory surface of the crown and the implant bed.

In the absence of conclusive evidence confirming which concept of the implant-denture retention is better, Sailer and co-workers decided to carry out a systematic review [10]. After analysing 59 papers selected from the yield of 4511, these authors did not obtain a clear answer. The researchers noted, however, that cemented reconstructions exhibited more serious biological complications, such as implant loss, alveolar bone loss, while screw-retained reconstructions exhibited more technical problems which resulted in the loss of the reconstruction but the implant could be reused. In the conclusion the authors stated that in the case of restorations reconstructing

single missing tooth both connecting methods can be used, however, restorations reconstructing the extensive loss should be screw-retained because of the difficulty in removing the residual cement, which can lead to periimplatitis and eventually to the loss of the implant.

In the case of the extensive tooth loss, when the pillars of prosthetic restoration are to be both the patient's own teeth and intra-osseous implants, it is possible to use screw-cement retention. Kosmin and co-workers [11] present a case of their own patient in whose mouth they placed a bridge in the maxilla (4 patient's own teeth and 6 intra-osseous implants) and a bridge in the mandible (2 natural teeth and 4 implants). The restorations were cemented with temporary cement on the patient's own teeth and screw in the case of implants. The five-year follow-up period showed no complications, only in the case of the mandible after 3 years the bridge was taken down in order to conduct the endodontic treatment of the canine. The removal of the bridge did not constitute a problem because of the screw-cement retention.

Many authors have a critical attitude to the idea of linking natural teeth with intra-osseous implants with fixed restoration. Their argument is the disproportion in the mobility of both types of pillars. Biomechanical differences between implants and natural teeth combined into one functional unit by means of a permanent restoration may result in the overload of implant pillars. In turn, physiological mobility of teeth can lead to the situation in which restorations come off the natural pillars resulting in leakage and caries.

The casting process often leads to residual stress and distortion of metal structures of fixed restorations. The scale of this phenomenon depends on the extent of the prosthetic restoration. A thin layer of connecting material used in cement-retained restorations gives the possibility of eliminating these inaccuracies to some extent. This is crucial in order to ensure passive adherence of the restoration to prosthetic pillars. In screw-retained restorations the potential stress resulting from the inaccuracies of metal structures is transferred directly to the implants. This results in bone loss around implants and may contribute to the development of periimplantitis. The connection of prosthetic abutments during restoration requires special attention in order to maintain passivity. That neutrality of prosthetic superstructure ensures long survival of implants in the patient's mouth. It should be stressed that each step is equally important. The end result depends on the quality of surgery, impressions and laboratory performance.

The aim of this study was to present prosthetic restoration combining the features of both screw-retained and cement-retained reconstruction. The authors made an attempt to combine the advantages of both types of the construction. The presented concept eliminates the lack of passivity arising at the stage of casting the metal structure. The technique is applicable in the case of using a large number of implants (over 4) connected together into a non-removable structure with the absence of parallelism of intra-osseous implants. This procedure is an alternative for new systems levelling the lack of parallelism, for example iBridge. The rule of conduct in the design of the described system is the use of two types of connections of abutments with the prosthetic construction; cemented and screwed ones.

Standard connecting elements were used in the restoration and the connecting elements were milled in such a way as to obtain the parallelism of the walls of as many abutments as possible with a minimum loss of volume of the connecting element, taking into account the point of exit for access holes. The authors would like to mention that a single connecting element should be minimally milled. Connecting elements with an access hole located at the side of the palate are designed as screw-retained, the others are cemented with temporary cement. The whole structure ensures high passivity (flexible properties of temporary cement) and possibility of the removal of the restoration, e.g. for hygienisation. It is also cheaper than the CAD/CAM technology what is important for patients.

The case description

The patient, a 67 year old man, came to the local clinic for prosthetic treatment. After the presentation of

the treatment plan, and its acceptance by the patient, the surgery stage began. Six implants were implanted in the toothless mandible. After the five month period of osseointegration the prosthetic phase of the treatment started. The impression of the mandible was taken using silicone impression material in the open-tray technique. In addition, the functional impression was made with the mouth closed (Fig. 1 and 2). After placing the models in the articulator the laboratory stage of the prosthetic restoration fabrication began with the help of an arbitrary facial arc (Fig. 3). As mentioned above, standard connecting elements were used (Fig. 4). While trying to obtain the parallelism of the abutments care was taken to mill the mesostructure as little as possible (Fig. 5). In the prosthetic suprastructure an access hole was made above each connecting elements (Fig. 6, 7, 8, 9). The connecting elements with a satisfactory degree of parallelism were connected with the suprastructure at the laboratory stage using long lasting prosthetic cement. The other abutments were connected with the prosthetic restoration at the clinical stage using temporary cement. Access holes were closed and the occlusal surface was restored with composite material.

Conclusions

1. The method of fabrication of structures on implants presented by the authors can be an alternative to the use of CAD/CAM systems.

Fig. 1.
Silicone impression in the open-tray technique

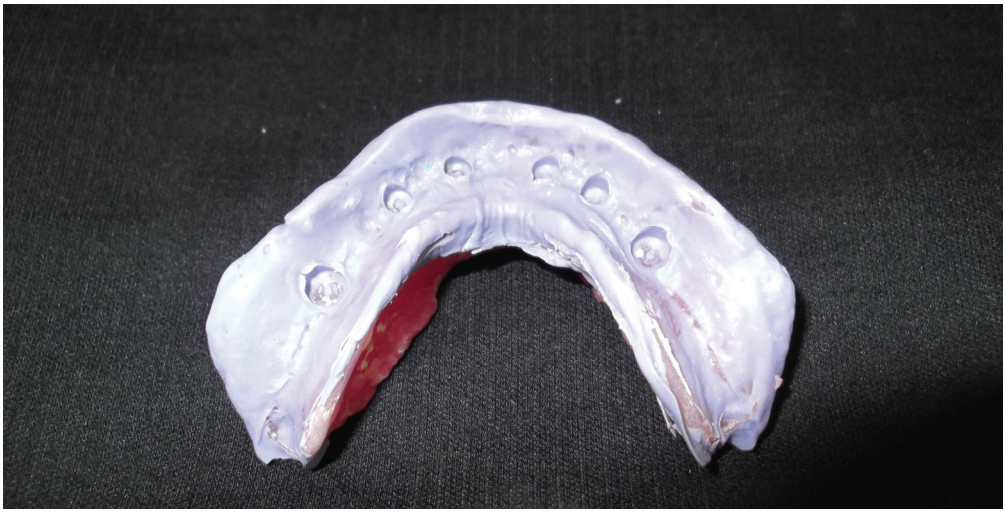

Fig. 2.
Functional impression



Fig. 3.
Models in the semi-adjustable articulator

Fig. 4.
The plaster model of the mandible with standard connecting elements

Fig. 5.
The plaster model of the mandible with milled connecting elements

Fig. 6.
Prosthetic restoration suprastructure

Fig. 7.
Restoration suprastructure with PFM

Fig. 8.
Restoration suprastructure with PFM

Fig. 9.
Restoration suprastructure with PFM

2. Further research is needed on the presented method especially as far as the use of temporary cement is concerned.

References

1. Jung RE, Pjetursson BE, Glauser R, Zembic A, Zwahlen M, Lang NP. A systematic review of the 5-year survival and complication rates of implant-supported single crowns. Clin Oral Implants Res. 2008 Feb; 19(2): 119–30
2. Pjetursson BE, Brägger U, Lang NP, Zwahlen M. Comparison of survival and complication rates of tooth-supported fixed dental prostheses (FDPs) and implant-supported FDPs and single crowns (SCs). Clin Oral Implants Res. 2007 Jun;18 Suppl 3: 97–113
3. Albrektsson T, Zarb G, Worthington P, Eriksson AR. The long-term efficacy of currently used dental implants: a review and proposed criteria of success. Int J Oral Maxillofac Implants. 1986; 1(1): 11–25
4. Büchter A, Joos U, Wiesmann H-P, Seper L, Meyer U. Biological and biomechanical evaluation of interface reaction at conical screw-type implants. Head Face Med. 2006 Feb 21; 2: 5
5. Sharifi MN, Pang IC, Chai J. Alternative restorative techniques of the CeraOne single-tooth abutment: a technical note. Int J Oral Maxillofac Implants. 1994; 9(2): 235-8
6. Linkevicius T, Vindasiute E, Puisys A, Peciuliene V. The influence of margin location on the amount of undetected cement excess after delivery of cement-retained implant restorations. Clin Oral Implants Res 2011; 22(12): 1379-84
7. Wilson JTG. The positive relationship between excess cement and peri-implant disease: A prospective clinical endoscopic study. J Periodontol 2009; 80(9): 1388-92
8. Keith SE, Miller BH, Woody RD, Higginbottom FL. Marginal discrepancy of screw-retained and cemented metal-ceramic crowns on implants abutments. Int J Oral Maxillofac Implants 1999; 14(3): 369-78
9. Torrado E, Ercoli C, Mardini MA, Graser GN, Tallents RH, Cordaro L. A comparison of the porcelain fracture resistance of screw-retained and cement-retained implant-supported metal-ceramic crowns. J Prosthet Dent 2004; 91(6): 532-7
10. Sailer I, Mühlemann S, Zwahlen M, Hämmerle CHF, Schneider D. Cemented and screw-retained implant reconstructions: a systematic review of the survival and complication rates. Clin Oral Implants Res 2012; 23: 163-201
11. Advantages of Combined Cemented and Screw-Retained Implant Supported Prosthesis. A Clinical Report [Internet]. [cited 2016 Jan 6]. Available from: http://medcraveonline.com/JDHODT/JDHODT-02-00037.php